

Custom Ablation for Irregular Astigmatism

We studied highly irregular corneas to address the special requirements of treating complex cases with irregular astigmatism.

BY ALEKSANDAR STOJANOVIC, MD

Consistent technological and surgical skill improvements have led to excellent outcomes and very low enhancement rates in modern laser refractive surgery. Consequently, most surgeons' refractive experience is limited to treatments in mainly uncomplicated virgin cases. Unfortunately, when we apply the same reasoning and technology to complex secondary cases with irregular astigmatism, results become more inconsistent, and cases may even deteriorate.

There could be several reasons why the common technology and techniques that work so well on virgin eyes do not work as well in the treatment of irregular astigmatism. First, the most current diagnostic equipment for custom data acquisition is often not capable of detecting all the necessary features of an irregular cornea, since it is fine-tuned to detect details in virgin eyes. Second, the software's ablation-planning strategy assumes optimization of intact preoperative optics and not a restoration of distorted optics. Finally, surgical techniques and equipment are for treatment of virgin eyes.

In an ongoing study at the University Hospital of North Norway, in Tromsø, we attempted to circumvent the above-mentioned obstacles and address the special requirements that we thought were necessary to treat complex cases with irregular astigmatism. First, we found the optimal method of registering relevant preoperative information in eyes with irregular astigmatism. After a decentration of corneal optics, the eye attempts to compensate for the visual distortion and rotates into a new fixating position. This results in a change of corneal intercept and inclination of fixation axis (Figures 1 and 2). Consequently, a map of a fixating eye with decentered optics, acquired by monocular plaido topography and/or aberrometry, would give us a reference to the eye position, as previously described. It would also constrain our treatment options to optimization of the corneal/eye optics reflecting that position and possibly lead to unnecessary corneal tissue consumption.¹ Therefore, we based our

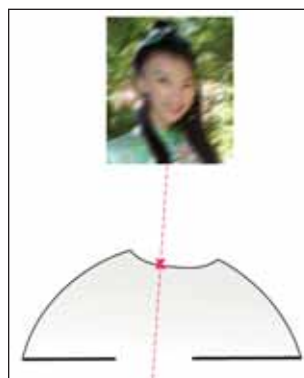


Figure 1. An eye with decentered corneal optics, seeing through its primary visual axis, results in a very distorted image.

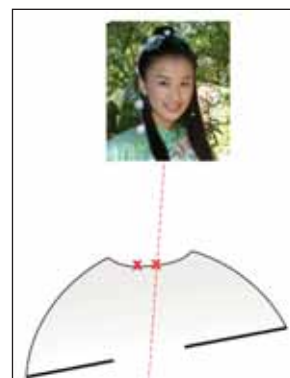


Figure 2. The same eye, seeing through its adapted visual axis, results in a less distorted image.

custom data on corneal morphology (ie, altimetry data), mapped independently of the rotational position of a fixating eye. For that purpose, we used elevation topography maps (calculated by triangulation) instead of wavefront aberrometry or monocular plaido-based topography that provides a single shot of the eye/corneal optics bound to the line of sight or fixation axis, respectively.

For custom ablation planning, we used Corneal Interactive Programmed Topographic Ablation (CIPTA; Ligi, SpA, Taranto, Italy), instead of wavefront-based software, which is common for treatment of virgin eyes. CIPTA compiled an ablation pattern, aiming to transform the actual corneal shape into a regular aspheric shape of desired curvature with a customized transition toward the untreated area. CIPTA software allows customization of parameters including tilt, centration, asphericity, and optical and transition size. The surgeon may then choose and fit the desired corneal shape in a variety of ways.

In our study of highly irregular corneas, we chose the morphological axis (ie, a computer-generated approxima-

tion of the primary optical symmetry of the cornea) as the ablation-fitting axis, since it seems to be the least invasive approach.¹ To achieve the smoothest transition toward the untreated cornea, the software customizes the transition area, providing a constant gradient of curvature change more than 360° by taking into account corneal shape outside the ablation area. As a preferred surgical technique for treatment of irregular astigmatism, we used transepithelial surface ablation; the epithelial removal with excimer laser was an integral part of the ablation plan. We added a constant 75- μm ablation depth to the compiled custom ablation plan to allow for maximum epithelial thickness. Alternatively, Artemis measurements (Ultralink LLC, St. Petersburg, Florida) of the actual maximum epithelial thickness were used in patients who underwent that examination. A modified LaserSight AstraScan (LaserSight Technologies, Inc., Winter Park, Florida) excimer laser was used for treatments. It is a flying spot laser system with a 0.6-mm Gaussian spot, 200-Hz frequency, and video-based eye tracker. The laser modification concerned its ability to read ablation maps generated by CIPTA within a matrix of 10,000 points, with the pupil center used as a common reference point between CIPTA and the laser. Additionally, to avoid cyclotorsional error, the CIPTA protocol required definition of horizontal axis during all relevant preoperative examinations, as well as the cyclotorsional alignment of the eye during the treatment. These were with respect to defined horizontal axis.

We studied 100 eyes (100 patients) treated for visual disturbances after decentered ablation, irregular ablation, insufficient effective optical zone, interface irregularities, irregular astigmatism after other types of eye surgery, injuries, and keratitis. Patients were recruited through referral by other eye departments, private clinics, or practicing ophthalmologists in Norway or abroad. Indications for treatment were visual disturbances related to changes in corneal topography

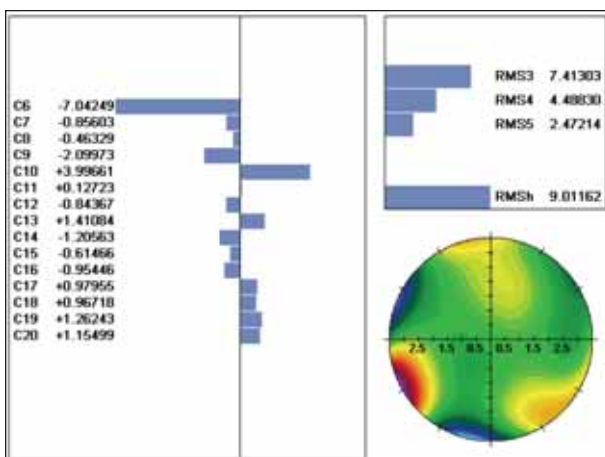


Figure 3. Preoperative higher-order aberrations.

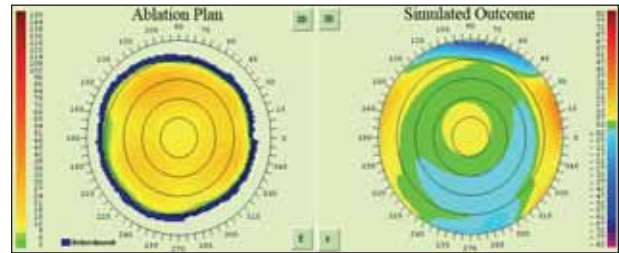


Figure 4. An ablation plan and simulated outcome, as shown by the anterior corneal floating elevation map.

that were categorized into the following three groups: (1) multiplopia and halos, (2) night vision disturbances including glare and starburst, and (3) decreased UCVA by spectacles or soft contact lenses. Correlation between the symptoms and the main corneal topography feature are summarized in Table 1. Topographic changes were analyzed by comparing preoperative and postoperative maps as well as simulated and achieved outcome maps.

Twelve months after surgery, no eye available for evaluation lost lines of BSCVA ($n=66$), while 50% gained lines, and 26% gained two or more lines. The safety index (ie, ratio between post- and preoperative BSCVA) was 1.27. Low-contrast BCVA improved by 58% (mean, 0.45 to 0.77; decimal scale converted from logMAR). The measured efficacy of our treatment was the amount of visual disturbances after the surgery. Table 2 shows the experienced change in visual disturbances compared with the preoperative level.

CASE STUDY

A 30-year-old male special force policeman with low myopia and 7-mm scotopic pupil was first treated with bilateral LASIK 12 months before referral to our clinic. The surgery was uneventful, except for a free—allegedly well-repositioned—cap in his right eye. His postoperative UCVA was 20/20, and he was near emmetropic in both eyes. The patient was seriously disturbed by multiple images, halos, and night vision problems in his right eye, which led to disability leave.

Corneal topography of his right eye showed a relatively well-centered ablation, but there were numerous paracentral irregularities, and the corneal asphericity was oblate with a Q-index of 0.87. Both first-surface Zernike analysis of elevation topography and wavefront aberrometry showed a significant increase in higher-order aberrations, especially fifth- and third-orders, as well as increased positive spherical aberration. Wavefront aberrometry showed root mean square of higher-order aberration coefficients six to 20 at 9.01 μm (Figure 3). We concluded that the most probable cause of this patient's irregular astigmatism was an erroneously repositioned (rotated) free cap. Transepithelial ablation on top of the LASIK flap was performed, aiming for a new opti-

plan on. This would result in unpredictable outcomes. The transepithelial ablation technique requires not only the software that would add a stipulated (or Artemis-measured) maximum epithelial depth to the custom ablation plan, but also a fast laser with a spot and energy distribution that results in a smooth ablation surface.

The last-mentioned feature may be the most important, because of its impact on minimizing the chances of postop haze. Our clinic has upgraded to a 1,000-Hz IVis-Suite laser (Ligi, SpA), which is actually built with custom transepithelial surface ablation in mind, so that it creates a smoother surface in a fraction of the time, when compared with the system used in this study.

One remaining problem with the topography-guided approach is that the spherocylindrical portion of the treatment, which is necessary to achieve the aimed refractive endpoint, relies on measuring the subjective refraction in the midst of higher-order aberrations, omnipresent in cases with irregular astigmatism. Unfortunately, wavefront aberrometry measurements, which should ideally provide objective information on lower-order aberrations, seem to lack reliability in highly aberrated cases, if at all possible to be acquired. Our treatments showed a high level of safety and efficacy. Most importantly, our patients' preoperative visual disturbances were decreased or eliminated. ■

Aleksandar Stojanovic, MD, is in charge of refractive surgery at the Eye Department, University Hospital of North Norway, in Tromsø. Dr. Stojanovic states that he has no financial interest in the products or companies mentioned. He may be reached at tel: +47 90 69 33 19; fax: +47 77 64 79 29; or aleks@online.no.

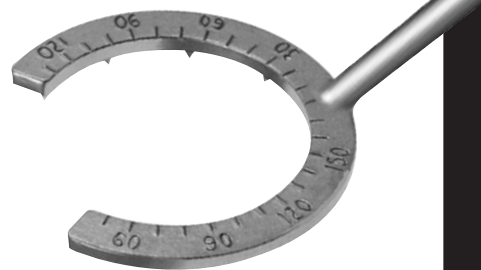
1. Stojanovic A, Suput D. Strategic Planning in Topography-guided Ablation of Irregular Astigmatism After Laser Refractive Surgery. *J Refract Surg*. 2005;21:369-376.

LRI Instruments

from Katena

Incision Guide with Fixation

This instrument is designed to serve as a guide for the placement of limbal relaxing incisions. The anterior surface of the ring features identification marks in 10° increments for gauging the length of the arcuate incision, while the posterior surface has delicate blunt teeth to fixate the globe. It also features an 8mm opening for the placement of a clear cornea incision while stabilizing the globe.




K3-6158 Lu-Mendez Incision Guide

Designed by Luis Lu, MD, of St. Mary's, PA

Gem Quality Diamond Knives

These knives feature titanium handles and gem quality 1mm wide diamond blades with 6-facet double bevel edges for bi-directional cutting. The single, highly polished footplate provides a smooth gliding surface and serves as a depth guard while permitting full visualization of the blade. The combination of these features allows the surgeon to make a clean and accurate limbal relaxing incision at a precise depth.



Katena offers three models of these LRI knives to meet the surgical requirements of any physician.



K2-6518 LRI Step Knife, 600 micron depth setting

K2-6519 LRI Step Knife, 500, 550 and 600 micron depth settings



K2-6522 LRI Micrometer Knife
depth settings from 0 to 1.5mm in 10 micron increments



katena products, inc.

4 Stewart Court, Denville, NJ 07834 • USA ☎ 973-989-1600 • 800-225-1195
FAX 973-989-8175 • www.katena.com • email globe@katena.com